

Special article

Clinical Management of Hepatocellular Carcinoma. Conclusions of the Barcelona-2000 EASL Conference

Jordi Bruix^{*}, Morris Sherman, Josep M. Llovet, Michel Beaugrand, Riccardo Lencioni, Andrew K. Burroughs, Erik Christensen, Luigi Pagliaro, Massimo Colombo, Juan Rodés, for the EASL Panel of Experts on HCC

Organizing Committee of the Conference: Henri Bismuth, Luigi Bolondi, Jordi Bruix and Daniel Shouval

Hepatocellular carcinoma (HCC) is a neoplasm the incidence of which is increasing worldwide, but striking geographical differences are observed for both risk factors and occurrence [1]. HCC represents more than 5% of all cancers and the estimated annual number of cases exceeds 500 000. It mostly affects patients with liver cirrhosis and currently represents their most common cause of death. Its clinical relevance and the existence of several diagnostic and therapeutic controversies explain the huge interest raised by this neoplasm. This prompted the European Association for the Study of the Liver (EASL) to organize a Monothematic Conference on Clinical Management of Hepatocellular Carcinoma, which was held in Barcelona in September 2000. During the meeting, a panel of international experts (Appendix A) met to prepare the present document that gives up-dated guidelines for the current clinical practice, and an overview of those aspects that should be the target of future clinical research.

1. Incidence and risk factors

The incidence in developing countries is two to three times higher than in developed countries. In Eastern Asia and Middle Africa the Age-Adjusted Incidence Rate (AAIR) ranges from 20 to 28 cases per 10^5 in men, while this is less than five per 10^5 in Northern Europe, Australia and America [1]. However, a steady increase has been observed in North America [2], but figures are still lower than in Southern Europe where the AAIR is around ten per 10^5 in men [1]. The calculation of the risk associated with any epidemiological or clinical variable is difficult to establish. Most studies on the incidence of HCC are uncontrolled

and are clinically based, rather than population based. Thus, relevant predictors in the general population may remain undetected. Male sex is associated with a higher incidence. The incidence also increases with age, probably a surrogate for the duration of the underlying liver disease. However, the most powerful risk factor is the existence of liver cirrhosis regardless of its etiology [3]. Amongst cirrhotics, viral infection and high alcohol intake are associated with the highest risk [4–7]. In Caucasian hepatitis B virus (HBV) carriers, HCC occurs most often in the setting of cirrhosis [8,9], but in Africa and South-East Asia, where the HBV infection is acquired early in life and coincides with other oncogenic agents (i.e. aflatoxin) [10], HCC may develop more frequently in a non-cirrhotic liver [11]. The annual incidence of HCC in HBV cirrhotics exceeds 2%, while in chronic carriers without cirrhosis the incidence varies between 0.4 and 0.6% [8,11–13]. In patients with hepatitis C virus (HCV) infection the increased risk appears to coincide with the establishment of cirrhosis, when the yearly incidence varies between 3 and 8% [5–7,14–16]. Genetic hemochromatosis carries an increased risk (5% annual incidence) following development of cirrhosis [17,18]. Male patients with primary biliary cirrhosis have an increased risk when they develop cirrhosis [19]. The incidence in autoimmune cirrhosis and Wilson disease is poorly defined and apparently is lower than in other etiological groups.

Aflatoxin intake has a role in the genesis of HCC only in patients who have pre-existing chronic hepatitis B [10]. The effect of smoking is hard to measure [20], while chronic oral contraceptive pills are not associated with a higher incidence of HCC [21].

Once cirrhosis is established the main HCC predictors are male sex and increased levels of alpha-fetoprotein (AFP) [5,16,22]. HCV viral genotype [14], increased concentration of AFP fractions or of other tumor markers [23–25], presence of macroregenerative nodules [26], dysplasia [27,28] or irregular regeneration in liver biopsy [29], or

^{*} Corresponding author. BCLC Group, Liver Unit, Digestive Disease Institute, Hospital Clínic, IDIBAPS, Villarroel 170, 08036 Barcelona, Catalonia, Spain. Tel.: +34-3-2275499; fax: +34-3-4515522.

E-mail address: jbruix@clinic.ub.es (J. Bruix).

immunohistochemical studies reflecting a higher proliferation index may provide additional predictive power [30], but this needs extensive confirmation. Accordingly, all individuals with cirrhosis are at increased risk of HCC and thus may be considered for surveillance. Cirrhosis may be easily diagnosed in the presence of a nodular liver with evident portal hypertension and liver decompensation. However, in the early stages it may be impossible to accurately distinguish between stage 3 fibrosis [31] and cirrhosis. Accurate non-invasive clinical and biochemical diagnostic criteria for cirrhosis have not been established and it is not justified to perform repeated liver biopsies just to initiate surveillance upon cirrhosis confirmation. Accordingly, in the routine clinical setting one could consider starting surveillance at an advanced fibrotic stage when established cirrhosis is very likely.

2. Surveillance

Surveillance for HCC meets some but not all of the standard criteria for assessing the feasibility of instituting a cost-effective surveillance program for any disease [32]. HCC occurs sufficiently frequently in some at-risk populations and it induces significant morbidity and mortality. In the Western world, the population at risk readily accepts the need for screening, and physicians generally do believe that surveillance is necessary. However, the surveillance tests are imperfect, and recall procedures are not well established. Finally, although therapy is not highly effective, it is curative in some patients. HCC surveillance aims to decrease disease-specific mortality, but this has not yet been demonstrated through a prospective randomized controlled trial (RCT) comparing surveillance to no surveillance. Such a follow-up study would need thousands of subjects. Given the widespread use of surveillance in formal and informal programs, the risk of contamination of the 'no surveillance' group is so high as to preclude the study from ever being completed at least in the West. Modeling data using up-to-date assumptions suggest that surveillance can be effective in reducing disease-specific mortality, with an acceptable cost-effectiveness among a selected group of patients [33,34]. Therefore, if the aim is to detect HCC in patients at a stage at which potentially effective treatment can be offered (this includes surgical resection, liver transplantation and percutaneous destruction), then the patients who should undergo surveillance should be those cirrhotics who would be treated if diagnosed with HCC. Those who are not suitable for curative therapy should not enter the program. Thus, the ideal target population is Child–Pugh's class A cirrhotic patients without any severe associated condition. Child–Pugh's C patients should be considered for liver transplantation. If this is not available or the patients are not candidates, surveillance is pointless. Whether Child–Pugh's B cirrhotics should undergo surveillance is controversial. If transplantation is not available,

there are no data to indicate that survival is enhanced, even if small HCC can be cured. Finally, it has to be stressed that improvement in treatment has and will come only by treating patients with early detected tumors and this is a noteworthy benefit of surveillance.

2.1. Surveillance tools

The available data on tumor growth suggest that the time from an undetectable lesion to 2 cm is about 4–12 months [35–38]. Thus, with an aim of detecting tumors below 3 cm in diameter, the suggested interval for surveillance in patients with cirrhosis has been set at 6 months. Patients with a particularly high risk do not warrant a more intense surveillance schedule since a higher risk does not mean faster tumor growth. The surveillance tools are AFP concentration and ultrasonography (US) [39]. AFP is not a very good screening test since it has a sensitivity of 39–64%, a specificity of 76–91% and a positive predictive value of 9–32% [34,39,40]. Its use as a surveillance test has not been as well studied. The value of the glycosylated fractions of AFP or other tumor markers has yet to be established unequivocally.

US is a much better surveillance tool than AFP. As a screening test in HbsAg carriers, US has a sensitivity of 71% and specificity of 93%, but its positive predictive value is only 14% [34]. Newer techniques such as contrast-enhanced US are currently not suitable for surveillance and the use of computed tomography (CT) is too expensive and invasive. An important aspect of surveillance is the expertise of the operator performing US examinations. For practical and economic reasons, the follow-up US ideally should be done within the community and not in tertiary hospitals. However, US surveillance for HCC requires specific training to acquire the degree of expertise to enable efficient use of the diagnostic capabilities of the modern equipment. If the necessary expertise is not available, the efficacy of surveillance will be lost, solely because of the poor application of otherwise effective resources. Upon detection of a suspicious nodule or an increase in AFP, the recommended policy is to evaluate the patients in referral centers with the optimal human and technical resources.

3. Recall procedures and diagnostic confirmation

There are no studies to define unequivocally the best recall policy, but based on the available clinical data the following scheme is advised (Fig. 1). The detection of a hypo- or hyperechoic nodule during follow-up US should raise the suspicion of HCC. However, pathological studies have shown that half of the nodules less than 1 cm in size do not correspond to HCC [41]. In addition, even if such a nodule corresponded to a true HCC, it is almost impossible to correctly diagnose it as such with the current diagnostic tools. Thus, from the clinical point of view a reasonable

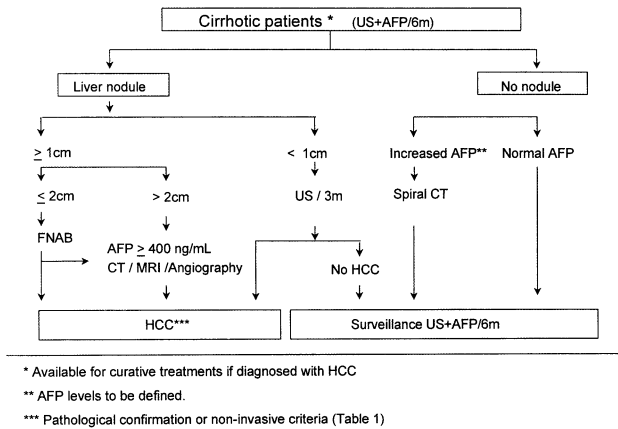


Fig. 1. Surveillance and recall strategy for HCC.

protocol in these cases is to repeat US every 3 months, until the lesion grows to >1 cm, at which point additional diagnostic techniques can be applied. However, the absence of growth during the follow-up period does not rule out a malignant nature of the nodule because even an early HCC may take more than 1 year to increase in size. When the nodule exceeds 1 cm in size, the lesion is more likely to be HCC and confirmation of diagnosis and staging should be pursued. If the nodule does not exceed 2 cm, biopsy of the nodule is recommended since the imaging techniques do not have sufficient accuracy to distinguish HCC from other benign or malignant conditions and the AFP concentration will usually remain within normal values or be slightly elevated. Pathological confirmation may be obtained by cytology or histology, but the combination of both techniques offers the highest diagnostic accuracy [42,43]. For nodules above 2 cm imaging techniques may confidently establish the diagnosis without needing confirmation with a positive biopsy [44–48]. In fact, a negative biopsy of a nodule visible with imaging techniques in a cirrhotic liver can never be taken as a criterion to rule out malignancy. Thus, in the setting of liver cirrhosis, HCC can be diagnosed by the coincident findings in at least two techniques (out of US, CT and magnetic resonance imaging (MRI)) showing characteristic features in a focal lesion >2 cm. Imaging techniques should evidence arterial hypervascularization and angiography can be used for this purpose if the others are not available (Table 1). Ultimately, the decision to request a diagnostic biopsy should take into account the clinical impact of the result, and the balance between the potential risks of biopsy if using a fine needle [49] and the risk of invasive treatments (i.e. transplantation) in a patient due to a possible false positive diagnosis based solely on imaging techniques. Finally, it has to be stressed that tumor biopsies at early stages may constitute a unique research tool to validate, in the clinical setting, the findings of experimental studies. Thus, in the future, tumor biopsy may become a useful tool for the molecular profiling of the disease. The HCC nature of a nodule may also be confirmed

by the concomitant detection of an increased AFP concentration. Published data suggest using values above 400 ng/ml for diagnostic confirmation, but future investigations may prompt a reduction of this limit to lower values, probably considered in comparison with values obtained prior to the nodule detection [40]. This is relevant since patients with chronic viral hepatitis may present transient increases of AFP coinciding with inflammatory flares of the disease and also sustained elevations in the absence of HCC. Any surveillance protocol using AFP should be devised to almost eliminate the potential for false positive results in terms of HCC diagnosis under these circumstances. While diagnostic AFP levels will seldom be observed in patients with HCC detected during surveillance, it will be more usual to detect minor elevations above normal values, without a positive US finding. There are no data to support the use of a specific AFP cut-off to indicate additional diagnostic investigations. In patients with normal AFP at baseline who have an increase above 20 ng/ml during follow-up, in the absence of a positive US, it would be worthwhile to perform a triple phase CT scan to rule out an HCC not detected by US. In most cases, the CT scan will be negative, but a persistently increased AFP would classify the patient as a very high-risk individual, so that the CT scan would provide a baseline liver examination to compare with subsequent imaging evaluations during follow-up. If AFP increases steadily, additional diagnostic techniques may be considered but no well defined algorithm can be suggested, because no studies have been reported in this area.

4. Assessment of disease extension

The indication to have accurate staging depends on the clinical need. In patients diagnosed at an advanced stage of disease with no therapeutic options, the results of diagnostic US provide enough information and no other techniques are necessary. In those individuals in whom a treatment decision has to be taken, tumor staging should be based on US and spiral CT. The use of lipiodol CT is not recommended because of its limited accuracy [50,51]. CT should be done with latest generation equipment using thin liver slices without contrast and during the arterial, venous and equilibrium phases after contrast administration [46]. Dynamic MRI

Table 1
Diagnostic criteria for HCC

Cyto-histological criteria
Non-invasive criteria (restricted to cirrhotic patients)
1. Radiological criteria: two coincident imaging techniques ^a Focal lesion >2 cm with arterial hypervascularization
2. Combined criteria: one imaging technique associated with AFP Focal lesion >2 cm with arterial hypervascularization AFP levels >400 ng/ml

^a Four techniques considered: US, spiral CT, MRI and angiography.

may substitute for CT scanning. The selection of the preferred approach should be based on local technical resources. The improvements in CT and MRI equipment have reduced the clinical usefulness of angiography, which should not be used routinely. Tissue-specific agents for MRI should be further investigated to define their clinical utility [52,53]. The usefulness of positron emission tomography is not established. Assessment of tumor spread in selected patients (i.e. candidates for liver transplantation, inclusion in therapeutic trials) may require thin section spiral CT of the chest and bone scintigraphy.

5. Prognostic assessment

The ideal system to estimate the prognosis of patients diagnosed with HCC should be as simple as possible to use, and yet include all important descriptive information associated with survival. Since the goal is to improve the prognosis by using a therapeutic intervention and because the possible interventions depend on the stage of the disease, both the stage and the various types of intervention should ideally be built into the prognostic system. The prognostic models in their present state are not precise enough because (a) they contain variables with only weak prognostic information (epiphenomena) not central to the fundamental biochemical or molecular causes and effects of the disease, (b) they are mainly based on data variables recorded only at the time of diagnosis omitting later follow-up information, (c) as the variables may interact in a complex pattern, linear models may be too simple, and (d) many of the existing studies are retrospective reports describing the results of a given practice without a defined protocol, and the selection of the patients according to the specific therapeutic practice is often not well defined. Therefore, the present prognostic data and systems cannot provide a precise prognosis for individual patients and they can only provide a guide to the prognosis of groups of patients.

There are four main factors affecting prognosis: (a) the stage, aggressiveness and growth rate of the tumor; (b) the general health of the patient; (c) the liver function of the patient; and (d) the specific intervention. Because of the significance of all four main factors, those staging systems which omit some factors or use only one factor will have a poor predictive power. Thus, uni-dimensional systems such as the Child–Pugh [54], the TNM staging [55], Karnofsky [56] and Performance Status [57] are not very useful. In addition, the predictive power of general models covering all stages of the disease (i.e. Okuda staging [58]) is also modest. Although their simplicity make them clinically attractive, their efficacy in predicting outcome is very low. More recently, three new staging systems for HCC have been proposed [59–61]. These use two [59], three [60] or four [61] of the above factors. Although overcoming some of the limitations of the former classifications, the clinical efficacy of these staging systems should be confirmed prior

to recommending their wide use. The simplest and optimal solution would be to develop a prognostic model for each relevant evolutionary stage of the disease (early, intermediate-advanced and terminal) and model into each stage the variables related to each specific intervention.

6. Definitions within clinical studies

Clinical investigations aiming to provide the most accurate and useful information should include a detailed and comprehensive report of the descriptive variables of all patients included. The variables to be recorded and described in outcome research should include those parameters that have been identified as significant predictors in previous investigations (Table 2). The data should be collected and reported in a standardized way to allow assessment of the comparability between groups of patients from various centers and countries.

For the evaluation of the therapeutic effect, time zero should be the time of commencement of the intervention (randomization). This should be as close as possible to the time of diagnosis and to the timing of all the investigations performed to define the status of the patients. If there is a significant delay, it will be necessary to reassess the status at the time of randomization. Intention-to-treat analysis is mandatory, particularly in studies in which not all subjects selected for a therapy do ultimately receive it (i.e. liver transplantation).

Survival should be the primary end-point in phase III–IV studies and the sample size should be calculated according to the outcomes reported in modern series of patients corresponding to the disease stage that will become the target of intervention [61–63]. The time of death is well defined and not subject to any interpretation. Causes of death and their relation to the time of intervention should be documented. Secondary end-points such as response rate, recurrence rate, duration of response, disease-free survival, quality of life, deterioration of physical condition and tumor growth rate are weaker end-points since they depend on the particular criteria used for their definition, and on the investigator being able to register them sufficiently close to the time of their biological occurrence. Thus, if these end-points are thought to be necessary, their definition should be standardized internationally. The comparison of disease-free survival, although intuitively attractive, is not adequate since it combines two independent events (death and recurrence).

6.1. Assessment of treatment response

The local response to treatment is relevant for the investigation of new therapeutic options. The evaluation of surgery is not subject to controversy, but the assessment of loco-regional treatment (i.e. percutaneous and transarterial procedures) requires a careful assessment of the treated HCC by imaging techniques. Spiral CT at least 4 weeks

Table 2
Data to be included in clinical studies dealing with HCC patients

Epidemiological	Age, gender, underlying liver disease and etiology
Tumor description	Size, number of nodules, macroscopic vascular invasion, extrahepatic spread, AFP Pathological characteristics if available: size, capsule, differentiation degree, satellites, vascular invasion
Liver function	Bilirubin, AST, ALT, albumin, alkaline phosphatase, gamma-glutamyl-transpeptidase, BUN, serum creatinine, serum sodium, prothrombin time, platelet count Presence of ascites or encephalopathy Child–Pugh class
General health	Performance Status/Karnofsky Pain, constitutional syndrome

after the treatment is currently accepted as the standard imaging modality for this purpose [64]. Non-enhanced tumoral areas reflect tissue necrosis after treatment, whereas viable neoplastic cells are recognized by enhanced areas inside treated lesions [64]. Lipiodol administration may diminish the reliability of CT scans, while the accuracy of MRI is not affected. The accuracy of Color-Doppler US is not as good, even when using contrast agents. It is lower than that of spiral CT. New US technologies based on tissue–contrast interaction are promising but require proper evaluation. AFP is not always increased in HCC patients and thus it has a limited value for the assessment of response. However, in those individuals with increased values prior to therapy, complete response should be associated with a decrease of AFP levels.

6.2. Definitions of response

Local response to treatment is usually defined following the World Health Organisation (WHO) criteria [65] as follows: complete response (CR): complete disappearance of all known disease and no new lesions determined by two observations not less than 4 weeks apart; partial response (PR): >50% reduction in total tumor load of all measurable lesions determined by two observations not less than 4 weeks apart; stable disease (ST): does not qualify for CR/PR or progressive disease; progressive disease (PD): >25% increase in size of one or more measurable lesions or the appearance of new lesions. Objective responses include both CR and PR. Measurement of tumor load by simple bi-dimensional determinations of diameter is not accurate enough, since tumor necrosis due to treatment is not taken into account. In fact, extensive tumor necrosis may not be paralleled by a reduction in diameter of the lesion. Therefore, the estimation of the reduction in viable tumor volume (recognized by non-enhanced areas by spiral CT) should be considered the optimal method to assess the local response to treatment [64].

Duration of response is a critical issue. Recurrence within the treated nodule after an initial evaluation reporting CR should be re-classified as a treatment failure. This is known to occur in 10–30% of patients after achieving CR detected by spiral CT 4 weeks after percutaneous treatments.

7. Treatment

There are no data to propose a universal treatment algorithm to be implemented worldwide. If diagnosed at an early stage, patients should be considered for any of the available options that may provide a high rate of CR. If these are not feasible, patients should be included in prospective investigations, preferably RCTs aiming to identify therapies that ultimately may lead to a survival improvement. Each group, center or country must establish the best treatment approach for patients with HCC taking into account the local technological and therapeutic resources and skills.

7.1. Curative treatments

Surgical resection, liver transplantation and percutaneous techniques achieve a relatively high rate of CR in properly selected candidates and thus should be classified as curative/effective treatments. These options are assumed to improve the natural history of the disease, prolonging the survival of patients with single HCC smaller than 5 cm or three nodules smaller than 3 cm. Whether larger tumors may be successfully treated in terms of objective responses and survival has not been clarified. RCTs comparing these three options are lacking and thus the selection of a treatment algorithm has to be based on the analysis of prospective cohort studies assessing outcomes [66].

Surgical resection provides excellent results for solitary HCC in patients with very well preserved liver function [67–69]. Selection of Child–Pugh's A patients is not sufficient to identify the adequate candidates for resection and should be refined using further indicators [70]. Five-year survival in well selected patients with resectable HCC is around 50% [67–69], reaching a 70% rate in those with normal bilirubin concentration who do not have portal hypertension [71]. In these excellent candidates, the selection between resection and transplantation should take into account the available resources in terms of technical skills, experience and organ availability. The main problem of surgical resection as compared with orthotopic liver transplantation is the high recurrence rate that may exceed 50% at 3 years and 70% at 5 years [66–69]. Transplantation has the advantage of removing the diseased liver together with the tumor itself, a theoretical superiority that is counteracted

by the shortage of donors. Following listing for orthotopic liver transplantation, patients have to wait for a variable period of time during which the tumor may progress and preclude the operation [72]. This adverse event worsens the outcomes when an intention-to-treat analysis of orthotopic liver transplantation results is performed [71]. The efficacy of adjuvant therapy prior and after transplantation has not been tested within a RCT and thus solid evidence supporting this practice is lacking [73]. Living donor liver transplantation may overcome the shortness of donors. It may achieve similar results as cadaveric liver transplantation, although no specific data from a cohort of HCC candidates have been published [74].

Patients with decompensated cirrhosis or those with multinodular early disease (three nodules ≤ 3 cm) should not undergo resection, and liver transplantation should be the first approach. The 5-year survival of patients transplanted because of early HCC is the same as that in patients without malignancy (70% at 5 years) and the recurrence rate during follow-up is less than 25% [71,73,75,76]. Viral infection of the graft and cirrhosis development is a severe and unsolved problem in HCV carriers [77,78].

Percutaneous ethanol injection (PEI) is a well tolerated treatment with a high anti-tumoral efficacy in small solitary HCC [79–81]. PEI is highly effective for tumors of ≤ 3 cm in which an 80% CR rate can be expected [82]. Larger and/or multinodular tumors will less likely achieve a total tumor necrosis with PEI, the CR rate being around 50% in tumors of between 3 and 5 cm, and far lower in larger nodules [82–84]. Failures are due to incomplete ethanol infiltration related to inadequate placement of the needle and/or to the presence of intra-tumoral septa. The combination of arterial embolization followed by PEI has been claimed to increase the initial response rate [85], although further investigations are needed to demonstrate its actual impact on survival compared to PEI alone.

At present, ethanol injection should be considered the standard percutaneous technique. Thus, more expensive and invasive options such as radio-frequency [86], microwave [87], cryotherapy [88] or laser [89] should be compared with PEI through RCTs assessing not only initial tumor response, but also long-term survival and costs (Table 3). Radio-frequency thermal destruction (RF) is a promising technology. It might obtain similar or even better objective response rates as PEI with fewer sessions, but these benefits are counteracted by a higher rate of side effects and a lower applicability of the treatment due to the tumor location [90].

Recurrence after effective percutaneous treatment is as frequent as after surgical resection (50% at 3 years and above 70% at 5 years) [83,84,91]. Prevention of recurrence has been postulated with retinoids [92], intra-arterial I^{131} -labeled lipiodol [93], immunotherapy with autologous lymphocytes activated by interleukin-2 and antibody to D3 [94] and interferon [95]. However, all these promising results await extensive confirmation and thus additional trials with these or other agents are encouraged (Table 3).

There are no RCTs comparing surgical resection and ethanol injection. While some series report that survival after percutaneous treatment is usually lower than after surgical resection [69], some cohort studies have failed to detect a significant difference [91,96]. Observed differences might be due not only to a lesser treatment-related benefit, but also to the functional status of the underlying liver and the presence of associated conditions or an advanced age that prevented patients from qualifying for transplantation or resection. Cohort studies suggest that PEI improves the survival of Child–Pugh's A patients with small HCC, in whom the high rate of CR is associated with a 50% survival at 5 years [97–99]. Although there is no agreement on the indications for PEI, it can be recommended for the above described patients when surgery is precluded. Conversely, in subjects with advanced liver disease (Child–Pugh's B or C) the treatment of the tumor, even if successful, may not counteract the grim prognosis due to the underlying cirrhosis.

7.2. Treatment of intermediate-advanced HCC

Surveillance programs for HCC have increased the proportion of patients diagnosed at an early stage, even though half of all patients are still diagnosed at an intermediate-advanced tumor stage. This strata is composed by patients who do not qualify for curative options, but who have not reached a terminal stage as reflected by a heavily impaired liver function with intense physical deterioration. Their 3-year survival may range from 10% to as high as 50% [62,63] and they are the candidates to receive non-curative loco-regional or systemic treatments. There are no large RCTs (i.e. including 1000 or more patients) published in the HCC field. In addition, the few meta-analyses of pooled data reported [100,101] are hampered by the heterogeneity of the selection criteria and treatment schedules, and by the small size of even the best RCTs included. Around 50 RCTs have been published for HCC in cirrhosis, but most of them lack a control arm of conservative management. Transarterial embolization and tamoxifen administration are the two options that have been best

Table 3
Recommendations for treatment and research in HCC patients

Curative therapies (resection, liver transplantation, percutaneous treatments) are recommended for patients with early HCC
Multicentre large RCT are needed to assess
Primary and secondary prevention of HCC
Adjuvant therapies for surgical and percutaneous treatments
Comparison of percutaneous treatments
Efficacy of combination of agents and new treatments
Design and end-points of RCT
Primary end-point: survival
Secondary end-points: treatment response and quality of life
Stratification of patients prior to randomization
Inclusion of control groups of untreated patients when assessing palliative options

evaluated. Other approaches such as selective radiation [102] or octreotide administration [103] have been assessed in single investigations with negative or positive but unreliable results.

Six RCTs comparing arterial embolization alone or associated with chemotherapy using doxorubicin or cisplatin with no treatment or suboptimal control therapies have failed to identify a survival benefit, even in those patients with local response to treatment [104–109]. The lack of benefit may be due in part to the fact that the prognosis of these patients is not only related to the HCC itself, but also to cirrhosis; in addition, objective responses are not maintained as time goes by. Additional large RCTs are needed to clarify whether differences in the selection of patients or in treatment schedules, including new agent combinations, may result in a therapeutic benefit for at least a subgroup of HCC patients who are not surgical candidates (Table 3).

The administration of tamoxifen, an estrogen receptor blocker, was initially reported to improve survival in patients with advanced HCC [110,111]. However, this has not been confirmed by double-blind [112] large [113] investigations. Thus, tamoxifen administration should not be considered an effective therapy and no additional trials are needed. Anti-androgen therapy is ineffective [114,115]. The benefits of Interferon reported in Eastern patients [116] have not been reproduced in the West and the toxicity of this drug was found to be unacceptably high [117].

The activity of chemotherapy in patients with HCC is negligible. The selective administration into the hepatic artery of chemotherapeutic agents mixed or not with lipiodol does not increase efficacy, reduce toxicity or improve outcome [118–120]. Thus, new agents with relevant activity are needed and will have to be tested within RCTs (Table 3).

In summary, none of the available options offers an unequivocal survival benefit to patients with intermediate-advanced HCC. Multicenter RCTs to assess any potentially effective approach are needed and they should include an untreated control arm until a therapy with unequivocal impact on survival is identified.

8. Prevention of HCC

Vaccination against HBV has decreased the incidence of HCC in areas with high prevalence of this viral agent [121]. Other strategies for primary prevention of HCC (i.e. Oltipraz [122]) are being tested but no solid data are yet available. Antiviral treatment for chronic hepatitis decreases the proportion of patients developing cirrhosis [123] and this should reduce the long-term incidence of this neoplasm [124]. When cirrhosis is already established, there is no evidence supporting a preventive effect of drugs such as Interferon. The two available RCTs in cirrhotic patients include a small number of individuals and show opposite results [125–127]. The analysis of cohort studies comparing treated and untreated patients suggests a lower incidence of

HCC in treated cases [124,128]. However, the investigations are flawed because of their retrospective nature, the bias in selection of candidates to be treated and the heterogeneous characteristics of the patients in terms of liver disease severity and concomitant risk factors for disease progression and HCC development (age, sex, alcohol intake, and histological fibrosis). Accordingly, large prospective RCTs in patients with cirrhosis are needed to define the role of Interferon or other agents for the primary prevention of HCC (Table 3).

Appendix A. Members of the EASL panel of experts on HCC

Michel Beaugrand, Henri Bismuth, Luigi Bolondi, Jordi Bruix, Concepción Brú, Andrew K. Burroughs, Massimo Colombo, Erik Christensen, Antonio Craxi, Francoise Degos, Adrian diBisceglie, Rafael Esteban, Josep Fuster, Gregory Gores, Masamichi Kojiro, Riccardo Lencioni, Tito Livraghi, Josep M. Llovet, Peter Neuhaus, Luigi Pagliaro, Gustav Paumgartner, Juan Rodés, Didier Samuel, Morris Sherman, and Daniel Shouval.

References

- [1] Bosch FX, Ribes J, Borrás J. Epidemiology of primary liver cancer. *Semin Liver Dis* 1999;19:271–285.
- [2] El Serag HB, Mason AC. Rising incidence of hepatocellular carcinoma in the United States. *N Engl J Med* 1999;340:745–750.
- [3] Zaman SN, Melia WM, Johnson RD, Portmann BC, Johnson PJ, Williams R. Risk factors in development of hepatocellular carcinoma in cirrhosis: prospective study of 613 patients. *Lancet* 1985;1:1357–1360.
- [4] Poynard T, Aubert A, Lazizi Y, Bedossa P, Hamelin B, Terris B, et al. Independent risk factors for hepatocellular carcinoma in French drinkers. *Hepatology* 1991;13:896–901.
- [5] Colombo M, de Franchis R, Del Ninno E, Sangiovanni A, De Fazio C, Tommasini M, et al. Hepatocellular carcinoma in Italian patients with cirrhosis. *N Engl J Med* 1991;325:675–680.
- [6] Tsukuma H, Hiyama T, Tanaka S, Nakao M, Yabuuchi T, Kitamura T, et al. Risk factors for hepatocellular carcinoma among patients with chronic liver disease. *N Engl J Med* 1993;328:1797–1801.
- [7] Bolondi L, Sofia S, Siringo S, Gaiani S, Casali A, Zironi G, et al. Surveillance programme of cirrhotic patients for early diagnosis and treatment of hepatocellular carcinoma: a cost-effectiveness analysis. *Gut* 2001;48:251–259.
- [8] Fattovich G, Giustina G, Schalm SW, Hadziyannis S, Sanchez-Tapias J, Almasio P, et al. Occurrence of hepatocellular carcinoma and decompensation in Western European patients with cirrhosis type B. The EUROHEP Study Group on Hepatitis B Virus and Cirrhosis. *Hepatology* 1995;21:77–82.
- [9] Villa F, Raldini GM, Pasquinelli C. Risk factors for hepatocellular carcinoma in Italy. Male sex, hepatitis B virus, non-A non-B infection and alcohol. *Cancer* 2000;62:611–615.
- [10] Yeh FS, Yu MC, Mo CC, Luo S, Tong MJ, Henderson BE. Hepatitis B virus, aflatoxins, and hepatocellular carcinoma in Southern Guangxi, China. *Cancer Res* 1989;49:2506–2509.
- [11] Liaw YF, Tai DI, Chu CM, Lin DY, Sheen IS, Chen TJ, et al. Early detection of hepatocellular carcinoma in patients with chronic type B hepatitis. A prospective study. *Gastroenterology* 1986;90:263–267.
- [12] Beasley RP, Hwang LY, Lin CC, Chien CS. Hepatocellular carcinoma and hepatitis B virus. A prospective study of 22,707 men in Taiwan. *Lancet* 1981;2:1129–1133.
- [13] Sakuma K, Saitoh N, Kasai M, Jitsukawa H, Yoshino I, Yamaguchi

- M, et al. Relative risks of death due to liver disease among Japanese male adults having various statuses for hepatitis B s and e antigen/antibody in serum: a prospective study. *Hepatology* 1988;8:1642–1646.
- [14] Bruno S, Silini E, Crosignani A, Borzio F, Leandro G, Bono F, et al. Hepatitis C virus genotypes and risk of hepatocellular carcinoma in cirrhosis: a prospective study. *Hepatology* 1997;25:754–758.
- [15] Ikeda K, Saitoh S, Koida I, Arase Y, Tsubota A, Chayama K, et al. A multivariate analysis of risk factors for hepatocellular carcinogenesis: a prospective observation of 795 patients with viral and alcoholic cirrhosis. *Hepatology* 1993;18:47–53.
- [16] Degos F, Christidis C, Ganne-Carrie N, Farmachidi JP, Degott C, Guettier C, et al. Hepatitis C virus related cirrhosis: time to occurrence of hepatocellular carcinoma and death. *Gut* 2000;47:131–136.
- [17] Niederau C, Fischer R, Sonnenberg A, Stremmel W, Trampisch HJ, Strohmeyer G. Survival and causes of death in cirrhotic and in non-cirrhotic patients with primary hemochromatosis. *N Engl J Med* 1985;313:1256–1262.
- [18] Fargion S, Fracanzani AL, Piperno A, Braga M, D'Alba R, Ronchi G, et al. Prognostic factors for hepatocellular carcinoma in genetic hemochromatosis. *Hepatology* 1994;20:1426–1431.
- [19] Jones DE, Metcalf JV, Collier JD, Bassendine MF, James OF. Hepatocellular carcinoma in primary biliary cirrhosis and its impact on outcomes. *Hepatology* 1997;26:1138–1142.
- [20] Mori M, Hara M, Wada I, Hara T, Yamamoto K, Honda M, et al. Prospective study of hepatitis B and C viral infections, cigarette smoking, alcohol consumption, and other factors associated with hepatocellular carcinoma risk in Japan. *Am J Epidemiol* 2000;151:131–139.
- [21] MILTS. Oral contraceptives and liver cancer. Results of the Multi-centre International Liver Tumor Study. *Contraception* 1997;56:275–284.
- [22] Oka H, Tamori A, Kuroki T, Kobayashi K, Yamamoto S. Prospective study of alpha-fetoprotein in cirrhotic patients monitored for development of hepatocellular carcinoma. *Hepatology* 1994;19:61–66.
- [23] Sato Y, Nakata K, Kato Y, Shima M, Ishii N, Koji T, et al. Early recognition of hepatocellular carcinoma based on altered profiles of alpha-fetoprotein. *N Engl J Med* 1993;328:1802–1806.
- [24] Shiraki K, Takase K, Tameda Y, Hamada M, Kosaka Y, Nakano T. A clinical study of lectin-reactive alpha-fetoprotein as an early indicator of hepatocellular carcinoma in the follow-up of cirrhotic patients. *Hepatology* 1995;22:802–807.
- [25] Tsai SL, Huang GT, Yang PM, Sheu JC, Sung JL, Chen DS. Plasma des-gamma-carboxyprothrombin in the early stage of hepatocellular carcinoma. *Hepatology* 1990;11:481–488.
- [26] Hytioglou P, Theise ND, Schwartz M, Mor E, Miller C, Thung SN. Macroregenerative nodules in a series of adult cirrhotic liver explants: issues of classification and nomenclature. *Hepatology* 1995;21:703–708.
- [27] Ganne-Carrie N, Chastang C, Chapel F, Munz C, Pateron D, Sibony M, et al. Predictive score for the development of hepatocellular carcinoma and additional value of liver large cell dysplasia in Western patients with cirrhosis. *Hepatology* 1996;23:1112–1118.
- [28] Borzio M, Bruno S, Roncalli M, Mels GC, Ramella G, Borzio F, et al. Liver cell dysplasia is a major risk factor for hepatocellular carcinoma in cirrhosis: a prospective study. *Gastroenterology* 1995;108:812–817.
- [29] Shibata M, Morizane T, Uchida T, Yamagami T, Onozuka Y, Nakano M, et al. Irregular regeneration of hepatocytes and risk of hepatocellular carcinoma in chronic hepatitis and cirrhosis with hepatitis-C-virus infection. *Lancet* 1998;351:1773–1777.
- [30] Borzio M, Trere D, Borzio F, Ferrari AR, Bruno S, Roncalli M, et al. Hepatocyte proliferation rate is a powerful parameter for predicting hepatocellular carcinoma development in liver cirrhosis. *Mol Pathol* 1998;51:96–101.
- [31] Bedossa P, Poynard T. An algorithm for the grading of activity in chronic hepatitis C. The METAVIR Cooperative Study Group. *Hepatology* 1996;24:289–293.
- [32] Prorok PC. Epidemiologic approach for cancer screening. Problems in design and analysis of trials. *Am J Pediatr Hematol Oncol* 1992;14:117–128.
- [33] Sarasin FP, Giostra E, Hadengue A. Cost-effectiveness of screening for detection of small hepatocellular carcinoma in Western patients with Child-Pugh class A cirrhosis. *Am J Med* 1996;101:422–434.
- [34] Collier J, Sherman M. Screening for hepatocellular carcinoma. *Hepatology* 1998;27:273–278.
- [35] Yoshino M. Growth kinetics of hepatocellular carcinoma. *Jpn J Clin Oncol* 1983;13:45–52.
- [36] Sheu JC, Chen DS, Sung JL, Chuang CN, Yang PM, Lin JT, et al. Hepatocellular carcinoma in the early stage. *Radiology* 1985;155:463–467.
- [37] Ebara M, Ohto M, Shinagawa T, Sugiura N, Kimura K, Matsutani S, et al. Natural history of minute hepatocellular carcinoma smaller than three centimeters complicating cirrhosis. A study in 22 patients. *Gastroenterology* 1986;90:289–298.
- [38] Barbara L, Benzi G, Gaiani S, Fusconi F, Zironi G, Siringo S, et al. Natural history of small untreated hepatocellular carcinoma in cirrhosis: a multivariate analysis of prognostic factors of tumor growth rate and patient survival. *Hepatology* 1992;16:132–137.
- [39] Okuda K. Early recognition of hepatocellular carcinoma. *Hepatology* 1986;6:729–738.
- [40] Sherman M. Alpha-fetoprotein: an obituary. *J Hepatol* 2001;34:603–605.
- [41] Nakashima T, Kojiro M. *Hepatocellular carcinoma*. Tokyo: Springer-Verlag, 1987.
- [42] Huang GT, Sheu JC, Yang PM, Lee HS, Wang TH, Chen DS. Ultrasound-guided cutting biopsy for the diagnosis of hepatocellular carcinoma – a study based on 420 patients. *J Hepatol* 1996;25:334–338.
- [43] Longchamp E, Patriarche C, Fabre M. Accuracy of cytology vs. microbiopsy for the diagnosis of well-differentiated hepatocellular carcinoma and macroregenerative nodule. Definition of standardized criteria from a study of 100 cases. *Acta Cytol* 2000;44:515–523.
- [44] Torzilli G, Minagawa M, Takayama T, Inoue K, Hui AM, Kubota K, et al. Accurate preoperative evaluation of liver mass lesions without fine-needle biopsy. *Hepatology* 1999;30:889–893.
- [45] Yu JS, Kim KW, Kim EK, Lee JT, Yoo HS. Contrast enhancement of small hepatocellular carcinoma: usefulness of three successive early image acquisitions during multiphase dynamic MR imaging. *Am J Roentgenol* 1999;173:597–604.
- [46] Kim T, Murakami T, Takahashi S, Tsuda K, Tomoda K, Narumi Y, et al. Optimal phases of dynamic CT for detecting hepatocellular carcinoma: evaluation of unenhanced and triple-phase images. *Abdom Imaging* 1999;24:473–480.
- [47] Lim JH, Kim CK, Lee WJ, Park CK, Koh KC, Paik SW, et al. Detection of hepatocellular carcinomas and dysplastic nodules in cirrhotic livers: accuracy of helical CT in transplant patients. *Am J Roentgenol* 2000;175:693–698.
- [48] Nino-Murcia M, Olcott EW, Jeffrey RB, Lamm RL, Beaulieu CF, Jain KA. Focal liver lesions: pattern-based classification scheme for enhancement at arterial phase CT. *Radiology* 2000;215:746–751.
- [49] Kim SH, Lim HK, Lee WJ, Cho JM, Jang HJ. Needle-tract implantation in hepatocellular carcinoma: frequency and CT findings after biopsy with a 19.5-gauge automated biopsy gun. *Abdom Imaging* 2000;25:246–250.
- [50] Mion F, Grozel L, Boillot O, Paliard P, Berger F. Adult cirrhotic liver explants: precancerous lesions and undetected small hepatocellular carcinomas. *Gastroenterology* 1996;111:1587–1592.
- [51] Bizollon T, Rode A, Bancel B, Gueripel V, Ducerf C, Baulieux J, et al. Diagnostic value and tolerance of Lipiodol-computed tomography for the detection of small hepatocellular carcinoma: correlation with pathologic examination of explanted livers. *J Hepatol* 1998;28:491–496.

- [52] Lencioni R, Mascalchi M, Caramella D, Bartolozzi C. Small hepatocellular carcinoma: differentiation from adenomatous hyperplasia with color Doppler US and dynamic Gd-DTPA-enhanced MR imaging. *Abdom Imaging* 1996;21:41–48.
- [53] Ward J, Guthrie JA, Scott DJ, Atchley J, Wilson D, Davies MH, et al. Hepatocellular carcinoma in the cirrhotic liver: double-contrast MR imaging for diagnosis. *Radiology* 2000;216:154–162.
- [54] Pugh RN, Murray-Lyon IM, Dawson JL, Pietroni MC, Williams R. Transection of the oesophagus for bleeding oesophageal varices. *Br J Surg* 1973;60:646–649.
- [55] Sobin LH, Wittekind C, editors. TNM classification of malignant tumours: International Union Against Cancer (UICC) 5th ed. New York: Wiley-Liss, 1997. p. 74.
- [56] Mor V, Laliberte L, Morris JN, Wiemann M. The Karnofsky Performance Status Scale. An examination of its reliability and validity in a research setting. *Cancer* 1984;53:2002–2007.
- [57] Sorensen JB, Klee M, Palshof T, Hansen HH. Performance status assessment in cancer patients. An inter-observer variability study. *Br J Cancer* 1993;67:773–775.
- [58] Okuda K, Ohtsuki T, Obata H, Tomimatsu M, Okazaki N, Hasegawa H, et al. Natural history of hepatocellular carcinoma and prognosis in relation to treatment. Study of 850 patients. *Cancer* 1985;56:918–928.
- [59] The Cancer of the Liver Italian Program (CLIP) investigators. A new prognostic system for hepatocellular carcinoma: a retrospective study of 435 patients. *Hepatology* 1998;28:751–755.
- [60] Chevret S, Trinchet JC, Mathieu D, Rached AA, Beaugrand M, Chastang C. A new prognostic classification for predicting survival in patients with hepatocellular carcinoma. *J Hepatol* 1999;31:133–141.
- [61] Llovet JM, Bru C, Bruix J. Prognosis of hepatocellular carcinoma: the BCLC staging classification. *Semin Liver Dis* 1999;19:329–338.
- [62] Llovet JM, Bustamante J, Castells A, Vilana R, Ayuso MC, Sala M, et al. Natural history of untreated nonsurgical hepatocellular carcinoma: rationale for the design and evaluation of therapeutic trials. *Hepatology* 1999;29:62–67.
- [63] Villa E, Moles A, Ferretti I, Buttafoco P, Grottola A, Del Buono M, et al. Natural history of inoperable hepatocellular carcinoma: estrogen receptors' status in the tumor is the strongest prognostic factor for survival. *Hepatology* 2000;32:233–238.
- [64] Bartolozzi C, Cioni D, Donati F, Granai G, Lencioni R. Imaging evaluation of tumor response. In: Bartolozzi C, Lencioni R, editors. *Liver malignancies. Diagnostic and interventional radiology*, 1st ed. Berlin: Springer-Verlag, 1999. pp. 467–487.
- [65] Miller AB, Hoogstraten B, Staquet M, Winkler A. Reporting results of cancer treatment. *Cancer* 1981;47:207–214.
- [66] Llovet JM, Bruix J, Gores GJ. Surgical resection versus transplantation for early hepatocellular carcinoma: clues for the best strategy. *Hepatology* 2000;31:1019–1021.
- [67] LCSG. Predictive factors for long term prognosis after partial hepatectomy for patients with hepatocellular carcinoma in Japan. *Cancer* 1994;74:2772–2780.
- [68] Bismuth H, Majno PE. Hepatobiliary surgery. *J Hepatol* 2000;32:208–224.
- [69] Arii S, Yamaoka Y, Futagawa S, Inoue K, Kobayashi K, Kojiro M, et al. Results of surgical and nonsurgical treatment for small-sized hepatocellular carcinomas: a retrospective and nationwide survey in Japan. *Hepatology* 2000;32:1224–1229.
- [70] Johnson P, Bruix J. Hepatocellular carcinoma and the art of prognostication. *J Hepatol* 2000;33:1006–1008.
- [71] Llovet JM, Fuster J, Bruix J. Intention-to-treat analysis of surgical treatment for early hepatocellular carcinoma: resection versus transplantation. *Hepatology* 1999;30:1434–1440.
- [72] Pereira SP, Williams R. Limits to liver transplantation in the UK. *Gut* 1998;42:883–885.
- [73] Bismuth H, Majno PE, Adam R. Liver transplantation for hepatocellular carcinoma. *Semin Liver Dis* 1999;19:311–322.
- [74] Marcos A. Right lobe living donor liver transplantation: a review. *Liver Transpl* 2000;6:3–20.
- [75] Mazzaferro V, Regalia E, Doci R, Andreola S, Pulvirenti A, Bozzetti F, et al. Liver transplantation for the treatment of small hepatocellular carcinomas in patients with cirrhosis. *N Engl J Med* 1996;334:693–699.
- [76] Wall WJ. Liver transplantation for hepatic and biliary malignancy. *Semin Liv Dis* 2000;20:425–436.
- [77] Prieto M, Berenguer M, Rayon JM, Cordoba J, Arguello L, Carrasco D, et al. High incidence of allograft cirrhosis in hepatitis C virus genotype 1b infection following transplantation: relationship with rejection episodes. *Hepatology* 1999;29:250–256.
- [78] Feray C, Caccamo L, Alexander GJ, Ducot B, Gugenheim J, Casanovas T, et al. European collaborative study on factors influencing outcome after liver transplantation for hepatitis C. European Concerted Action on Viral Hepatitis (EUROHEP) Group. *Gastroenterology* 1999;117:619–625.
- [79] Livraghi T, Festi D, Monti F, Salmi A, Vettori C. US-guided percutaneous alcohol injection of small hepatic and abdominal tumors. *Radiology* 1986;161:309–312.
- [80] Shiina S, Tagawa K, Unuma T, Fujino H, Uta Y, Niwa Y, et al. Percutaneous ethanol injection therapy of hepatocellular carcinoma: analysis of 77 patients. *Am J Roentgenol* 1990;155:1221–1226.
- [81] Livraghi T, Giorgio A, Marin G, Salmi A, de Sio I, Bolondi L, et al. Hepatocellular carcinoma and cirrhosis in 746 patients: long-term results of percutaneous ethanol injection. *Radiology* 1995;197:101–108.
- [82] Vilana R, Bruix J, Bru C, Ayuso C, Sole M, Rodes J. Tumor size determines the efficacy of percutaneous ethanol injection for the treatment of small hepatocellular carcinoma. *Hepatology* 1992;16:353–357.
- [83] Ishii H, Okada S, Nose H, Okusaka T, Yoshimori M, Takayama T, et al. Local recurrence of hepatocellular carcinoma after percutaneous ethanol injection. *Cancer* 1996;77:1792–1796.
- [84] Castellano L, Calandra M, Del Vecchio Blanco C, de Sio I. Predictive factors of survival and intrahepatic recurrence of hepatocellular carcinoma in cirrhosis after percutaneous ethanol injection: analysis of 71 patients. *J Hepatol* 1997;27:862–870.
- [85] Lencioni R, Paolicchi A, Moretti M, Pinto F, Armillotta N, Di Giulio M, et al. Combined transcatheter arterial chemoembolization and percutaneous ethanol injection for the treatment of large hepatocellular carcinoma: local therapeutic effect and long-term survival rate. *Eur Radiol* 1998;8:439–444.
- [86] Goldberg SN, Gazelle GS, Solbiati L, Livraghi T, Tanabe KK, Hahn PF, et al. Ablation of liver tumors using percutaneous RF therapy. *Am J Roentgenol* 1998;170:1023–1028.
- [87] Sato M, Watanabe Y, Ueda S, Iseki S, Abe Y, Sato N, et al. Microwave coagulation therapy for hepatocellular carcinoma. *Gastroenterology* 1996;110:1507–1514.
- [88] Wong WS, Patel SC, Cruz FS, Gala KV, Turner AF. Cryosurgery as a treatment for advanced stage hepatocellular carcinoma: results, complications, and alcohol ablation. *Cancer* 1998;82:1268–1278.
- [89] Giorgio A, Tarantino L, de Stefano G, Farella N, Catalano O, Cusati B, et al. Interstitial laser photocoagulation under ultrasound guidance of liver tumors: results in 104 treated patients. *Eur J Ultrasound* 2000;11:181–188.
- [90] Livraghi T, Goldberg SN, Lazzaroni S, Meloni F, Solbiati L, Gazelle GS. Small hepatocellular carcinoma: treatment with radio-frequency ablation versus ethanol injection. *Radiology* 1999;210:655–661.
- [91] Castells A, Bruix J, Bru C, Fuster J, Vilana R, Navasa M, et al. Treatment of small hepatocellular carcinoma in cirrhotic patients: a cohort study comparing surgical resection and percutaneous ethanol injection. *Hepatology* 1993;18:1121–1126.
- [92] Muto Y, Moriwaki H, Ninomiya M, Adachi S, Saito A, Takasaki KT. Prevention of second primary tumors by an acyclic retinoid, polyprenoic acid, in patients with hepatocellular carcinoma. *N Engl J Med* 1996;334:1561–1567.
- [93] Lau WY, Leung TW, Ho SK, Chan M, Machin D, Lau J, et al. Adjuvant intra-arterial iodine-131-labelled lipiodol for resectable

- hepatocellular carcinoma: a prospective randomised trial. *Lancet* 1999;353:797–801.
- [94] Takayama T, Sekine T, Makuuchi M, Yamasaki S, Kosuge T, Yamamoto J, et al. Adoptive immunotherapy to lower postsurgical recurrence rates of hepatocellular carcinoma: a randomised trial. *Lancet* 2000;356:802–807.
- [95] Ikeda K, Arase Y, Saitoh S, Kobayashi M, Suzuki Y, Suzuki F, et al. Interferon beta prevents recurrence of hepatocellular carcinoma after complete resection or ablation of the primary tumor. A prospective randomized study of hepatitis C virus-related liver cancer. *Hepatology* 2000;32:228–232.
- [96] Livraghi T, Bolondi L, Buscarini L, Cottone M, Mazziotti A, Morabito A, et al. No treatment, resection and ethanol injection in hepatocellular carcinoma: a retrospective analysis of survival in 391 patients with cirrhosis. *J Hepatol* 1995;22:522–526.
- [97] Shiina S, Tagawa K, Niwa Y, Unuma T, Komatsu Y, Yoshiura K, et al. Percutaneous ethanol injection therapy for hepatocellular carcinoma: results in 146 patients. *Am J Roentgenol* 1993;160:1023–1028.
- [98] Lencioni R, Pinto F, Armillotta N, Bassi AM, Moretti M, Di Giulio M, et al. Long-term results of percutaneous ethanol injection therapy for hepatocellular carcinoma in cirrhosis: a European experience. *Eur Radiol* 1997;7:514–519.
- [99] Llovet JM, Bruix J, Capurro S, Vilana R, for the BCLC Group. Long-term survival after ethanol injection for small hepatocellular carcinoma in 100 cirrhotic patients. Relevance of maintained success. *J Hepatol* 1999;30:100A.
- [100] Mathurin P, Rixe O, Carbonell N, Bernard B, Cluzel P, Bellin MF, et al. Review article: overview of medical treatments in unresectable hepatocellular carcinoma – an impossible meta-analysis? *Aliment Pharmacol Ther* 1998;12:111–126.
- [101] Simonetti RG, Liberati A, Angiolini C, Pagliaro L. Treatment of hepatocellular carcinoma: a systematic review of randomized controlled trials. *Ann Oncol* 1997;8:117–136.
- [102] Raoul JL, Guyader D, Bretagne JF, Duvauferrier R, Bourguet P, Bekhechi D, et al. Randomized controlled trial for hepatocellular carcinoma with portal vein thrombosis: intra-arterial iodine-131-iodized oil versus medical support. *J Nucl Med* 1994;35:1782–1787.
- [103] Kouroumalis E, Skordilis P, Thermos K, Vasilaki A, Moschandrea J, Manousos ON. Treatment of hepatocellular carcinoma with octreotide: a randomised controlled study. *Gut* 1998;42:442–447.
- [104] Lin DY, Liaw YF, Lee TY, Lai CM. Hepatic arterial embolization in patients with unresectable hepatocellular carcinoma – a randomized controlled trial. *Gastroenterology* 1988;94:453–456.
- [105] Pelletier G, Roche A, Ink O, Anciaux ML, Derhy S, Rougier P, et al. A randomized trial of hepatic arterial chemoembolization in patients with unresectable hepatocellular carcinoma. *J Hepatol* 1990;11:181–184.
- [106] Madden MV, Krige JE, Bailey S, Beningfield SJ, Geddes C, Werner ID, et al. Randomised trial of targeted chemotherapy with lipiodol and 5-epidoxorubicin compared with symptomatic treatment for hepatoma. *Gut* 1993;34:1598–1600.
- [107] GETCH. A comparison of lipiodol chemoembolization and conservative treatment for unresectable hepatocellular carcinoma. *N Engl J Med* 1995;332:1256–1261.
- [108] Bruix J, Llovet JM, Castells A, Montana X, Bru C, Ayuso MC, et al. Transarterial embolization versus symptomatic treatment in patients with advanced hepatocellular carcinoma: results of a randomized, controlled trial in a single institution. *Hepatology* 1998;27:1578–1583.
- [109] Pelletier G, Ducreux M, Gay F, Luboinski M, Hagege H, Dao T, et al. Treatment of unresectable hepatocellular carcinoma with lipiodol chemoembolization: a multicenter randomized trial. *J Hepatol* 1998;29:129–134.
- [110] Farinati F, Salvagnini M, De Maria N, Fornasiero A, Chiamonte M, Rossaro L, et al. Unresectable hepatocellular carcinoma: a prospective controlled trial with tamoxifen. *J Hepatol* 1990;11:297–301.
- [111] Martinez Cerezo FJ, Tomas A, Donoso L, Enriquez J, Guarner C, Balanzo J, et al. Controlled trial of tamoxifen in patients with advanced hepatocellular carcinoma. *J Hepatol* 1994;20:702–706.
- [112] Castells A, Bruix J, Bru C, Ayuso C, Roca M, Boix L, et al. Treatment of hepatocellular carcinoma with tamoxifen: a double-blind placebo-controlled trial in 120 patients. *Gastroenterology* 1995;109:917–922.
- [113] CLIP Group. Tamoxifen in treatment of hepatocellular carcinoma: a randomised controlled trial. *Lancet* 1998;352:17–20.
- [114] Manesis EK, Giannoulis G, Zoumboulis P, Vafiadou I, Hadziyannis SJ. Treatment of hepatocellular carcinoma with combined suppression and inhibition of sex hormones: a randomized, controlled trial. *Hepatology* 1995;21:1535–1542.
- [115] Grimaldi C, Bleiberg H, Gay F, Messner M, Rougier P, Kok TC, et al. Evaluation of antiandrogen therapy in unresectable hepatocellular carcinoma: results of a European Organization for Research and Treatment of Cancer multicentric double-blind trial. *J Clin Oncol* 1998;16:411–417.
- [116] Lai CL, Lau JY, Wu PC, Ngan H, Chung HT, Mitchell SJ, et al. Recombinant interferon-alpha in inoperable hepatocellular carcinoma: a randomized controlled trial. *Hepatology* 1993;17:389–394.
- [117] Llovet JM, Sala M, Castells L, Suarez Y, Vilana R, Bianchi L, et al. Randomized controlled trial of interferon treatment for advanced hepatocellular carcinoma. *Hepatology* 2000;31:1–5.
- [118] Nerenstone SR, Ihde DC, Friedman MA. Clinical trials in primary hepatocellular carcinoma: current status and future directions. *Cancer Treat Rev* 1988;15:1–31.
- [119] Okada S, Okazaki N, Nose H, Yoshimori M, Aoki K. Prognostic factors in patients with hepatocellular carcinoma receiving systemic chemotherapy. *Hepatology* 1992;16:112–117.
- [120] Johnson PJ, Kalayci C, Dobbs N, Raby N, Metivier EM, Summers L, et al. Pharmacokinetics and toxicity of intraarterial adriamycin for hepatocellular carcinoma: effect of coadministration of lipiodol. *J Hepatol* 1991;13:120–127.
- [121] Chang MH, Chen CJ, Lai MS, Hsu HM, Wu TC, Kong MS, et al. Universal hepatitis B vaccination in Taiwan and the incidence of hepatocellular carcinoma in children. *N Engl J Med* 1997;336:1855–1859.
- [122] Kensler TW, He X, Otieno M, Egner PA, Jacobson LP, Chen B, et al. Oltipraz chemoprevention trial in Qidong, People's Republic of China: modulation of serum aflatoxin albumin adduct biomarkers. *Cancer Epidemiol Biomarkers Prev* 1998;7:127–134.
- [123] EASL. International Consensus Conference on Hepatitis C. Consensus statement. *J Hepatol* 1999;31(Suppl 1):3–8.
- [124] Imai Y, Kawata S, Tamura S, Yabuuchi I, Noda S, Inada M, et al. Relation of interferon therapy and hepatocellular carcinoma in patients with chronic hepatitis C. *Ann Intern Med* 1998;129:94–99.
- [125] Nishiguchi S, Kuroki T, Nakatani S, Morimoto H, Takeda T, Nakajima S, et al. Randomised trial of effects of interferon-alpha on incidence of hepatocellular carcinoma in chronic active hepatitis C with cirrhosis. *Lancet* 1995;346:1051–1055.
- [126] Valla DC, Chevallier M, Marcellin P, Payen JL, Trepo C, Fonck M, et al. Treatment of hepatitis C virus-related cirrhosis: a randomized, controlled trial of interferon alfa-2b versus no treatment. *Hepatology* 1999;29:1870–1875.
- [127] Nishiguchi S, Shiomi S, Nakatani S, Takeda T, Fukuda K, Tamori A, et al. Prevention of hepatocellular carcinoma in patients with chronic active hepatitis C and cirrhosis. *Lancet* 2001;357:196–197.
- [128] Baffis V, Shrier I, Sherker AH, Szilagyi A. Use of interferon for prevention of hepatocellular carcinoma in cirrhotic patients with hepatitis B or hepatitis C virus infection. *Ann Intern Med* 1999;131:696–701.